

# Nodular Prurigo UK

## About Nodular Prurigo

### Overview

Nodular Prurigo is a chronic skin condition characterised by intensely itchy (pruritic) nodules. With continuing scratching patients will often develop multiple excoriated lesions. Nodular prurigo is also known as:

- Prurigo Nodularis
- Hyde's Disease

The term Pickers Nodules has fallen into disrepute as it can stigmatise the individual.

### Causes

An overall cause for nodular prurigo has not been found. Many patients have a family history of atopic dermatitis. It is a '*Chicken and Egg*' condition where it is not clear whether scratching leads to the appearance of nodules or the nodules come first and cause the itching.

It is known that reaction to an insect bite or another form of dermatitis can lead to nodular prurigo and it is associated with emotional stress, iron deficiency anaemia, HIV, chronic renal failure, gluten enteropathy, mycobacterial infection, thyroid diseases and other conditions.

### Clinical Features

Nodular prurigo affects both sexes equally. Although it can occur at any age, in general it affects adults between the ages of 20 and 60 years.

Nodules are firm and between 1 and 3cm in diameter. They may have a scaly or warty surface. Nodules often start as a red, itchy lump. Older lesions may be darker or paler than the surrounding skin and those that have been scratched become crusty and covered with scale.

The itching is **intense** and can last for many hours without relief and often disturbs sleep. This is the most distressing aspect of the condition for the patient who can find it impossible not to scratch. Scratching has the added danger of introducing bacterial infection into the lesions which can make the itching worse.

Numbers of lesions can be from a one or two to a few hundred. Usually starting on the lower arms and legs they occur most commonly on the outer aspects of these. The trunk, back, buttocks, face and even the palms of the hands can become affected.

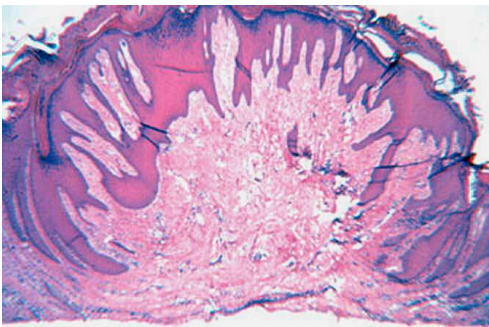
Although lesions may heal spontaneously with scarring, new lesions appear from time to time. Because this can become a chronic condition lasting many years, there is a high incidence of stress and depression.

## Investigations

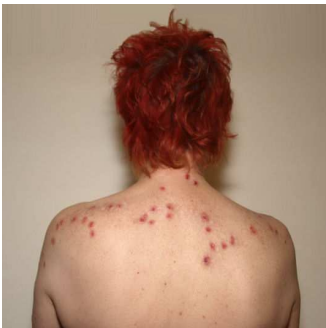NP is recognised primarily by clinical diagnosis and may be confirmed by taking a skin biopsy of one of the lesions. Further investigations are aimed at excluding any underlying medical cause for the itch and may include:

- Blood tests - full blood count, iron studies, liver function, kidney & thyroid function, HIV antibody
- Patch testing if contact dermatitis is suspected
- Liver ultrasound
- Nerve conduction studies
- Skin biopsy

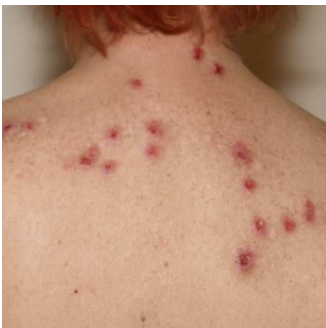## Images



1. Prurigo nodularis is an extreme response of the skin to chronic external trauma. This lesion is nodular at the surface of the skin; it has a central stalk composed of dense fibrous tissue. The epidermal patterns have a psoriasiform quality. Perivascular infiltrates of lymphoid cells are more prominent in the dermis, adjacent to the lesion, than in the stalk, or in the dermis beneath the lesion. The lesion has fibrokeratomatous qualities. Hyperplasia of peripheral nerves is sometimes mentioned as a requisite for the diagnosis of prurigo nodularis.



2. Nodules on shoulder and upper back.



3. Detail of Nodules: Note excoriated, indurated lesions due to scratching.